

DANCING AS A POTENTIAL INITIATOR OF EARLY HIP OSTEOARTHRITIS

Caecilia Charbonnier¹ and Jacques Menetrey²

Artanim Foundation, Medical Research Department, Geneva, Switzerland¹
Orthopedics and Trauma Service, University Hospital of Geneva, Switzerland²

We present a study carried out with professional female ballet dancers to better understand the potential factors leading to early hip osteoarthritis in this population. This research consisted in three study arms: a radiological examination, a clinical evaluation and a biomechanical analysis to provide a comprehensive assessment of the dancer's hip. We concluded that the practice of dancing movements could cause a loss of hip joint congruence and recurrent superior/posterosuperior femoroacetabular impingements, which could lead to early degenerative lesions in the morphologically normal hip.

KEY WORDS: motion capture, MRI, computer simulation, impingements, subluxation.

INTRODUCTION: Professional ballet dancers present a higher risk of developing hip osteoarthritis (OA) due to repetitive and extreme movements performed during their daily dancing activities (Binningsley, 2003; Groh & Herrera 2009). Early OA could be explained by femoroacetabular impingements (FAI) that occur when there is an abutment conflict between the proximal femur and the acetabular rim (Ganz et al., 2003) due to a non-spherical femoral head (cam impingement) or to acetabular overcoverage (pincer impingement). FAI induces early chondrolabral damages typically described as located in the anterosuperior quadrant of the acetabulum (Beaulé et al., 2005; Tannast et al., 2008).

FAI cannot explain observed OA in hips with normal morphology. However, repetitive microtrauma is believed to be one of the causes of the development of early OA in the young active adult (Mason, 2001). Indeed, sporting activities that require repetitive external rotation (Binningsley 2003; Mason, 2001) or hyperabduction (Groh & Herrera 2009; Santori & Villar, 2000) such as ballet, have been thought to result in labral tears. Moreover, a lack of joint congruency could be another potential cause of degenerative lesions.

To verify the aforementioned hypotheses and to better understand the possible factors leading to early OA in the dancer's hip, we performed a comprehensive radiological, clinical and biomechanical study with 20 female professional ballet dancers and a control group of 15 active healthy female. The purposes of this research were manifold: 1) to perform morphological measurements of the dancers' hips and to determine the prevalence of FAI lesions based on Magnetic Resonance Imaging (MRI); 2) to clinically evaluate dancers' hips with measurement of the passive range of motion (ROM), 3) to quantify the active ROM and congruence of the hip joint in typical dancing positions; 4) to detect and locate potential FAI during 3D simulation of the hip joint; and 5) to compare the kinematic and clinical results with the radiological findings.

MR IMAGING: The first research question was to evaluate the normality of the femoroacetabular morphology and to determine the prevalence of lesions in dancers and controls. MRI of the hip joint in supine position was hence carried out. For each subject, acetabular cartilage lesions and labral lesions were assessed and the presence of other abnormalities (e.g., cysts) was reported. The normality of both the femoral head and the acetabulum was measured according to radiographic criteria (Kolo et al., 2013), such as femoral alpha neck angle, acetabular depth and acetabular version. Our results concluded that the hip morphology was normal for dancers and controls, except for one dancer (cam morphology). MRI of dancer's hip revealed 3 types of lesions: labral tears, cartilage thinning, and pits (round cystic lesion). For more than 80% of the dancers' hips presenting lesions, labral and acetabular damages were diagnosed in the superior (61% and 77%, respectively)

and posterosuperior parts (22% and 8%, respectively) of the acetabulum – thus not in the anterosuperior position as it is generally the case in the cam or pincer hip.

We also used MRI to reconstruct patient-specific 3D models of the hip joint (pelvis, femur, cartilage surfaces and labrum) (Gilles et al., 2006) and to evaluate the congruency of the dancer's hip in split position. Additional MR images were thus acquired in this extreme position (Fig. 1) and a model-to-image registration technique (Gilles et al., 2009) was used to measure femoroacetabular translations. We found a femoroacetabular subluxation of 2.05 ± 0.74 mm (range 0.63-3.56 mm), suggesting that the hip undergoes significant stress in this extreme yet static dancing position.

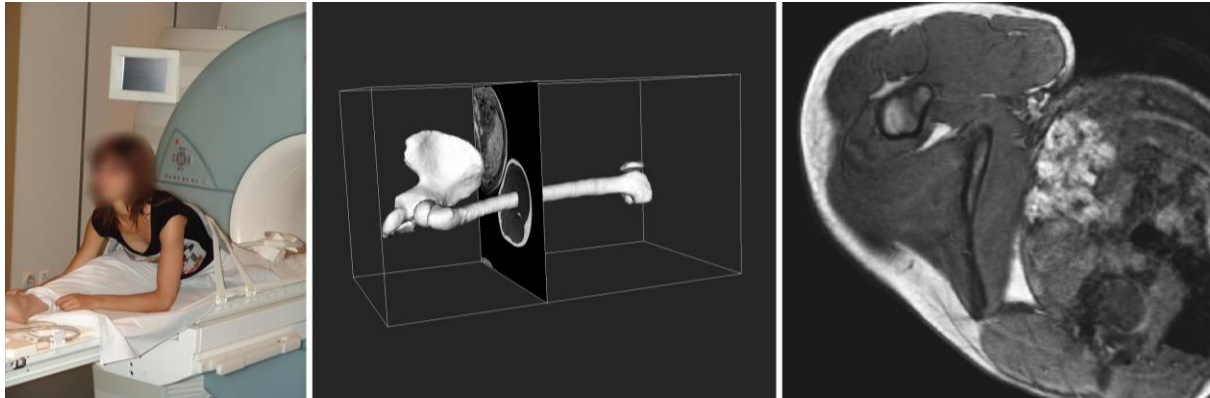


Figure 1: MRI in split position.

CLINICAL EVALUATION: The second research question was to understand the origin of hip pain in dancers and to assess their joint mobility compared to the control group. Participants had to complete a questionnaire (Duthon et al., 2013) about the presence and localization of hip pain, activities which triggered the pain, and evaluation of consecutive activity limitations (e.g., stairs climbing, sitting). The questionnaire also asked dancers about the chronological relation of the hip pain with their dancing activities. The passive ROM of the hip joint in the different directions (flexion/extension, abduction/ abduction, internal/external rotation) was clinically determined using a double-armed goniometer. Anterior and posterior impingement tests were also performed, looking at elicited pain.

According to our results, 12 of the 20 dancers complained of inguinal hip pain while dancing only. The dancers had a normal passive hip ROM, with a trend to increased abduction and external rotation (50% were over the normal range), and to decreased internal rotation (30% were below the normal range) – in relation to the “turnout” position (i.e., the basic position on which all ballet movement follows). Pain could be reproduced by the anterior impingement test for 9 of them. Control group was asymptomatic and impingement tests were not painful.

Correlation of clinical and MRI findings led to classify dancers in 4 groups: 1) pain and lesions on MRI (11 dancers), 2) pain and normal MRI (1 dancer), 3) no pain but lesions on MRI (7 dancers), 4) no pain and normal MRI (1 dancer). No correlation between symptoms and lesions on MRI was thus observed.

MOTION ANALYSIS: The third research question was to quantify the active ROM and congruence of the hip joint in typical dancing positions and to detect FAI in-vivo. Motion capture (Vicon system, 8 cameras) of the hip joint was hence carried out in 11 dancers. Data were acquired during 6 dancing movements: grand plié, développé à la seconde, développé devant, grand écart latéral, grand écart facial and arabesque. The hip joint kinematics was computed from the recorded markers trajectories, using a validated biomechanical model (Charbonnier et al., 2009) which accounted for skin motion artifacts and anatomical constraints (accuracy: translational error ≈ 0.5 mm, rotational error $<3^\circ$). The resulting

computed motions were applied to the dancer's hip joint 3D models reconstructed from their MRI data (Fig. 2A).

FAI was evaluated using a collision detection algorithm (Charbonnier et al., 2011) to virtually locate abnormal contacts between the femur and labrum. Moreover, the surface-to-surface distance (i.e., penetration depth) was computed to quantify the topographic extent of labral compression (Fig. 2B). The ROM and congruence of the hip joint were quantified in the 6 recorded dancing movements. Using the pelvic and femoral bone coordinate systems (Wu et al., 2002), normalized hip joint angles were determined at each point of the motion given the computed bone poses from motion capture data. The relative position between the hip bone and femur was described by making reference to a vector joining a point (i.e., the hip joint center) defined in each of the pelvic and the femoral frames (Fig. 2C).

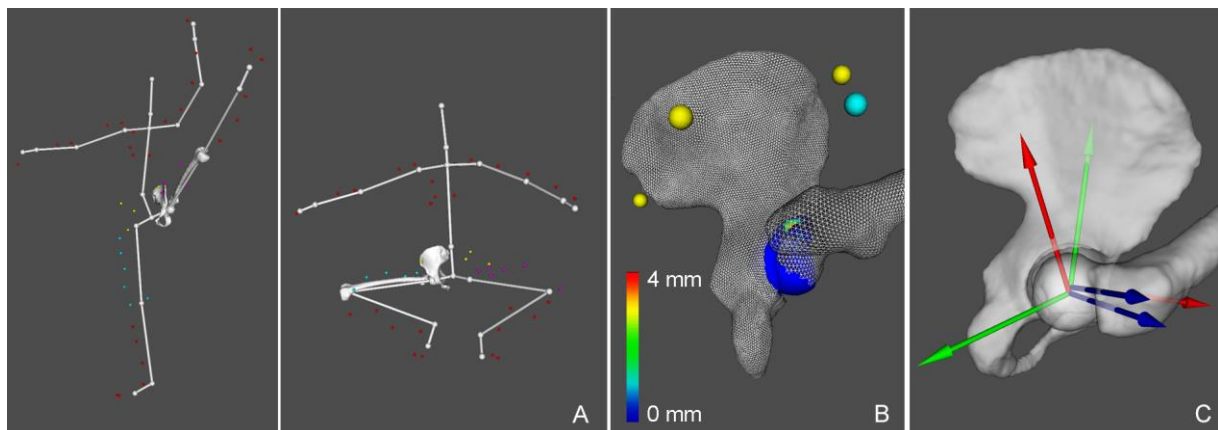


Figure 2: A) Computed dancing postures. B) Visualization of the FAI region with colors showing the penetration depth distribution. C) Femoroacetabular subluxation.

Dancing involves intensive hip flexion (mean: 84°; range: -42°–117°) and abduction (mean: 42°; range: 18°–73°) combined with rotation. The frequency of FAI and subluxation, and the amount of femoroacetabular translations and penetration depth varied with the type of movement (Table 1). Four dancing movements (développé à la seconde, grand écart facial, grand écart latéral and grand plié) seemed to create significant stress in the hip joint, according to the observed high frequency of impingement and amount of subluxation. The computed zones of FAI were mainly located in the superior or posterosuperior part of the acetabulum, which was relevant with respect to the MRI findings.

Table 1
Frequency of impingement and subluxation, amount (mean ± SD) of penetration depth and subluxation by movement

Movements	Freq. of FAI	Freq. of subluxation	Penetration depth (mm)	Subluxation (mm)
Arabesque	0%	0%	0	0
Développé devant	24%	6%	2.5 ± 1.2	0
Développé à la seconde	45%	25%	3.25 ± 1.91	4.56 ± 1.14
Grand écart facial	61%	39%	3.63 ± 2.55	3.42 ± 1.6
Grand écart latéral (front leg)	70%	31%	2.22 ± 1.83	5.14 ± 1.28
Grand écart lateral (back leg)	22%	11%	1.11 ± 1.33	3.15 ± 0
Grand plié	44%	17%	2.47 ± 1.76	3.77 ± 2.08

CONCLUSION: To become a professional ballet dancer, a morphologically normal hip is necessary. Only trained subjects are able to assume ballet dancing movements and this extreme motion is possible thanks to a combination of three articular motion patterns. With

the use of motion capture, we showed that FAI and subluxation were often observed in typical ballet positions, which was never demonstrated before. The diagnosed labral and acetabular lesions were typical lesions of femoroacetabular conflicts, but they were located in the superior or posterosuperior area of the acetabulum. The computed zones of FAI during simulation were relevant with those findings. We therefore concluded that dancing implies a new superior/posterosuperior FAI, and combined with subluxation it could lead to early OA. No criteria in the data explained why some dancers presented pain and/or femoroacetabular lesions while others did not. This discrepancy between clinical and MRI findings suggests the greatest caution if surgical treatment is only based on MRI findings. Early OA in dancer's hip could be prevented by limiting in frequency extreme movements implying femoroacetabular abutment. Following this study, we have undertaken measures to educate dancers, dancing teachers and choreographers about their technique to control extreme movements.

REFERENCES:

- Beaulé, P.E., Zaragoza, E., Motamedi, K., Copelan, N., Dorey, F.J. (2005). Three-dimensional computed tomography of the hip in the assessment of femoroacetabular impingement. *J Orthop Res*, 23(6), 1286-1292.
- Binningsley, D. (2003). Tear of the acetabular labrum in an elite athlete. *Br J Sports Med*, 37, 84-88.
- Duthon, V.B., Charbonnier, C., Kolo, F.C., Magnenat-Thalmann, N., Becker, C.D., Bouvet, C., Coppens, E., Hoffmeyer, P., Menetrey, J. (2013). Correlation of Clinical and MRI Findings in Hips of Elite Female Ballet Dancers. *Arthroscopy: The Journal of Arthroscopic and Related Surgery*, 29(3), 411-419.
- Charbonnier, C., Assassi, L., Volino, P., Magnenat-Thalmann, N. (2009). Motion study of the hip joint in extreme postures. *Vis Comput*, 25(9), 873-882.
- Charbonnier, C., Kolo, F.C., Duthon, V.B., Magnenat-Thalmann, N., Becker, C.D., Hoffmeyer, P., Menetrey, J. (2011). Assessment of Congruence and Impingement of the Hip Joint in Professional Ballet Dancers: A Motion Capture Study. *Am J Sports Med*, 39(3), 557-566.
- Ganz, R., Parvizi, J., Beck, M., Leunig, M., Nötzli, H., Siebenrock, K.A. (2003). Femoroacetabular impingement: a cause for osteoarthritis of the hip. *Clin Orthop Relat Res*, 417, 112-120.
- Gilles, B., Moccozet, L., Magnenat-Thalmann, N. (2006). Anatomical modelling of the musculoskeletal system from MRI. *MICCAI '06, Part II. LNCS, Springer Berlin / Heidelberg*, 4190, 289-296.
- Gilles, B., Kolo, F.C., Magnenat-Thalmann, N., Becker, C., Duc, S., Menetrey, J., Hoffmeyer, P. (2009). MRI-based assessment of hip joint translations. *J Biomech*, 42(9), 1201-1205.
- Groh, M.M. & Herrera, J. (2009). A comprehensive review of hip labral tears. *Curr Rev Musculoskelet Med*, 2, 105-117.
- Kolo, F.C., Charbonnier, C., Pfirrmann, C.W.A., Duc, S.R., Lubbeke, A., Duthon, V.B., Magnenat-Thalmann, N., Hoffmeyer, P., Menetrey, J., Becker, C.D. (2013). Extreme Hip Motion in Professional Ballet Dancers: Dynamic and Morphologic Evaluation Based on MRI. *Skeletal Radiol*, 42(5), 689-698.
- Mason, J.B. (2001). Acetabular labral tears in the athlete. *Clin Sports Med*, 20, 779-790.
- Santori, N., Villar, R.N. (2000). Acetabular labral tears: result of arthroscopic partial limbectomy. *Arthroscopy*, 16, 11-15.
- Tannast, M., Goricki, D., Beck, M., Murphy, S.B., Siebenrock, K.A. (2008). Hip damage occurs at the zone of femoroacetabular impingement. *Clin Orthop Relat Res*, 466, 273-280.
- Wu, G., Siegler, S., Allard, P., Kirtley, C., Leardini, A. et al. (2002). ISB recommendation on definitions of joint coordinate system of various joints for the reporting of human joint motion - Part I: Ankle, hip and spine. *J Biomech*, 35(4), 543-548.

Acknowledgements

We thank Dr. Victoria Duthon, Dr. Frank Kolo, Prof. Nadia Magnenat-Thalmann, Prof. Christoph Becker, Prof. Pierre Hoffmeyer, and the MIRALab's research team for their participation in this study.